











Vejledning til undersøgelse af hunde ved DDDs Brachycephal studie

Bilag 1: BCS

**BODY CONDITION SCORE
MEDIUM DOG**



TOO THIN		
 <p>1</p> <ul style="list-style-type: none"> Ribs, lumbar vertebrae, pelvic bones and all bony prominences evident from a distance No discernible body fat Obvious loss of muscle mass 	 <p>2</p> <ul style="list-style-type: none"> Ribs, lumbar vertebrae, and pelvic bones easily visible No palpable fat Some bony prominences visible from a distance Minimal loss of muscle mass 	 <p>3</p> <ul style="list-style-type: none"> Ribs easily palpable and may be visible with no palpable fat Tops of lumbar vertebrae visible, pelvic bones becoming prominent Obvious waist and abdominal tuck
IDEAL		ABOVE IDEAL
 <p>4</p> <ul style="list-style-type: none"> Ribs easily palpable with minimal fat covering Waist easily noted when viewed from above Abdominal tuck evident 	 <p>5</p> <ul style="list-style-type: none"> Ribs palpable without excess fat covering Waist observed behind ribs when viewed from above Abdomen tucked up when viewed from side 	 <p>6</p> <ul style="list-style-type: none"> Ribs palpable with slight excess of fat covering Waist is discernible when viewed from above but is not prominent Abdominal tuck apparent
OVERWEIGHT		OBESE
 <p>7</p> <ul style="list-style-type: none"> Ribs palpable with difficulty, heavy fat cover Noticeable fat deposits over lumbar area and base of tail Waist absent or barely visible Abdominal tuck may be absent 	 <p>8</p> <ul style="list-style-type: none"> Ribs not palpable under very heavy fat cover or palpable only with significant pressure Heavy fat deposits over lumbar area and base of tail Waist absent No abdominal tuck Obvious abdominal distension may be present 	 <p>9</p> <ul style="list-style-type: none"> Massive fat deposits over thorax, spine, and base of tail Waist and abdominal tuck absent Fat deposits on neck and limbs Obvious abdominal distension

Link til kilde: <https://www.royalcaninhealthyweight.co.uk/pet-obesity>

Bilag 2:

Vejtrækningslyde:

Grad 1: ingen mislyd/tegn på dyspnoe

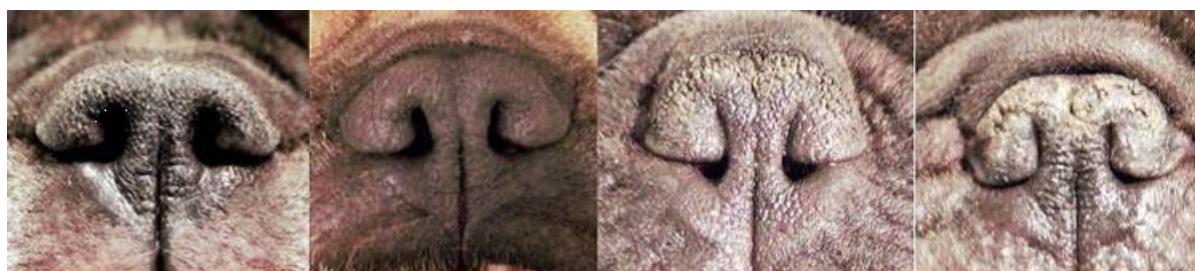Grad 2: intermitterende mislyde/tegn på dyspnoe

Grad 3: vejrtækning høres konstant under konsultationen

Halsomfang i cm:

Halsens omfang måles med målebånd 1cm bag underkæbe

Bilag 2: Næsebor graduering



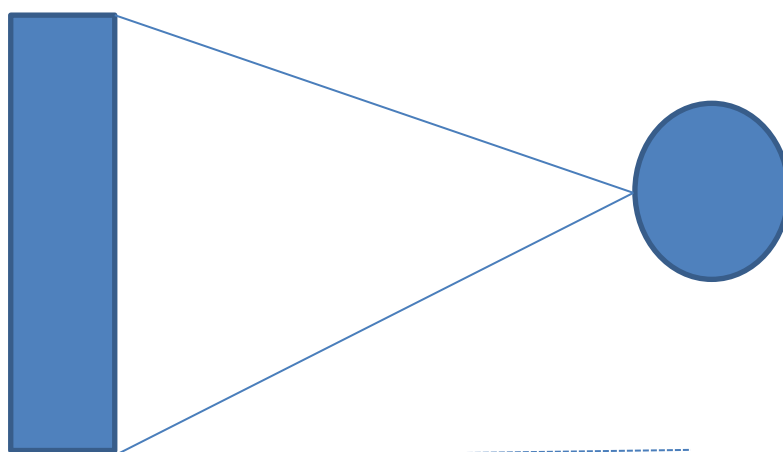
Grad 1	Grad 2	Grad 3	Grad 4
--------	--------	--------	--------

Foto: Line Lange Møller og Eva-Marie Ravn

Foto tages forfra på ca. 10-20 cm afstand

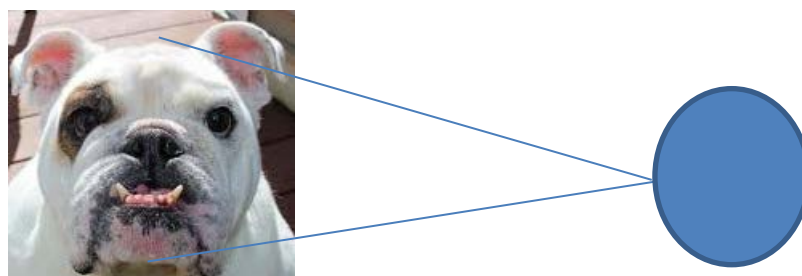
Bilag 3: Instruks til billeder

Instruks til kropsbillede



1 meter fra hunden,
på højde med skulder

Instruks til hovedbillede



30 cm fra hunden
På højde med øje